

Acute Epiglottitis in Adults-A Case Report

Hady TALL^{1*}, Ndiamé SARR², Fakhane Bineta TINE¹, Ngor NDOUR¹, Frédéric Kossinda³, Aliou FATY⁴

¹Ear Nose and Throat (ENT) department at Saint-Louis Regional Hospital Centre, Sénégal

²Anaesthesia and intensive care department at Saint-Louis Regional Hospital Centre, Sénégal

³Ear Nose and Throat (ENT) department at University Hospital Centre Maman Elisabeth Domiten de Bimbo (Central African Republic)

⁴Ear Nose and Throat (ENT) department at Luke Hospital, Diourbel, Sénégal

*Corresponding author: Dr Hady TALL, Adresse: Boulevard Mar Diop; 32002 Saint-Louis; Sénégal. Téléphone: (+221) 773178623; Email: dyhatall@yahoo.fr

Citation: TALL H, SARR N, TINE FB, NDOUR N, Kossinda F, et al. (2023) Acute Epiglottitis in Adults-A Case Report. Anna Clin Rev Cas Rep: ACRCR-113.

Received Date: August 03, 2023; **Accepted Date:** August 08, 2023; **Published Date:** August 08, 2023

Abstract

For a long period of time, acute epiglottitis has remained a specific pathology in little children. The introduction and globalization of the haemophilus influenzae type B vaccine has seen a drastic diminishing of its paediatric forms. Its occurrence in adults. On the other hand, its occurrence in adult is increasing with a clinical form and evolution which is noticeably different from child epiglottitis. It is a mainly male pathology which occurs most of the time between 40 to 50 years old. Its symptomatology is less typical and less noisy than that in children, which makes the evolution of the diagnosis, sometimes, difficult. The latter may be confirmed with nasofibroscopy by checking the epiglottis and the adjacent supra-glottic structures. A non-invasive treatment is most of the time possible, with a close monitoring in intensive care. In its severe cases, the therapeutic challenge is to keep upper airways free, if needed, after an intubation or tracheotomy. Morality is not much considered though a fatal evolution may occur through unpredictable hypoxic cardiac arrest, in case of upper airways' obstruction.

Keywords: adult epiglottitis, upper airways, laryngeal dyspnoea.

Introduction

Acute epiglottitis is an inflammation of the epiglottis which occurs suddenly. It is a rare urgent respiratory infection which can challenge the vital prognosis with the obstruction of the upper airways. Its occurrence in adults is extremely rare.

We are reporting here the case of a severe acute epiglottitis in adults, a patient who has been being treated at the ENT department of St-Louis Regional Hospital.

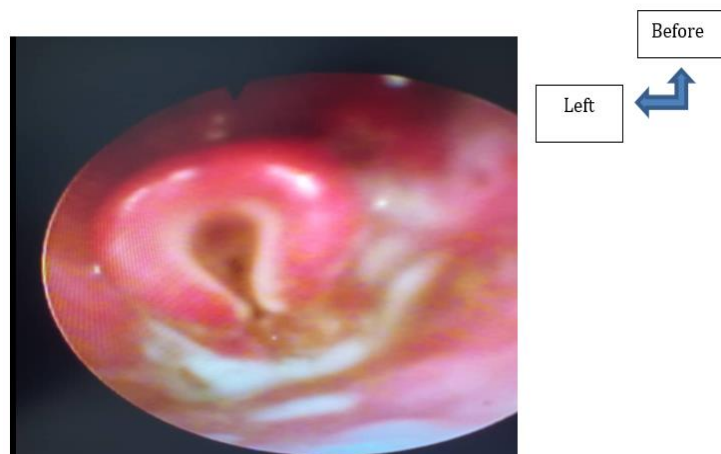
Observation

The patient is 49 years old, a driver living in the suburb of St-Louis, a non-insulin-dependent diabetic. He had been

referred to us by a colleague from the reception and emergency department for a laryngeal dyspnoea treatment associated with 4 days evolving dysphonia, odynophagia, and fever.

The admission test concretely showed a laryngeal dyspnoea with supra sternal and intercostal indrawing without stridor, a room air desaturation, SRIS, stinky secretions and an epiglottis lump filling the supra-glottic area when taking nasofibroscopy (figure 1). The rest of the clinical tests showed no particular sign.

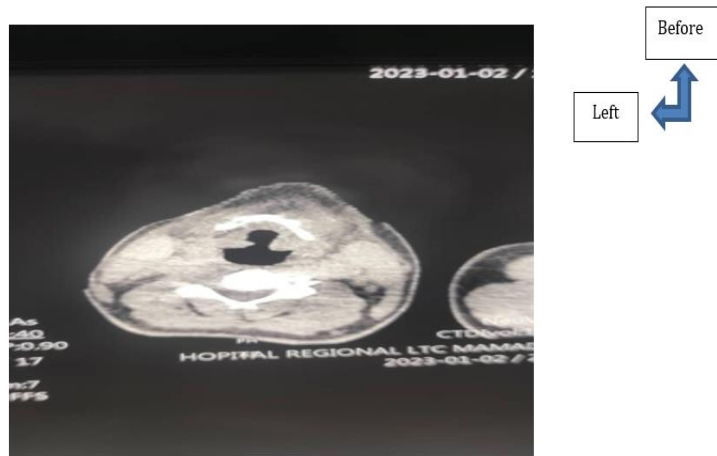
Figure 1: admission nasofibroscopy showing the epiglottitis or B (ary folds epiglottic oedema).



The biological test showed a non-specific biological inflammatory syndrome with a hyperleukocytosis and a neutrophils predominance. The check-up of the area

allowed establishing diabetes. The cervicothoracic CT showed a calm epiglottitis almost filling the total supra-glottis, the glottis and the sub-glottis were free (figure 2).

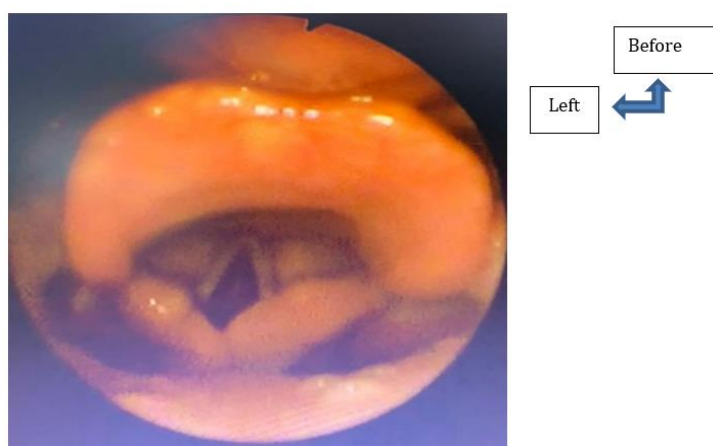
Figure 2: The cervicothoracic CT showed an epiglottic appesement almost filling the total supra-glottis.



The patient had initially been treated in an adapted condition, firstly, at the emergency department then at the

hospitalization department. The medication had showed a favourable evolution after 2 months (figure 3).

Figure 3: Check-up Nasofibrosopy after 2 months treatment.



Discussion

The most classical and probably the most known description of an infectious acute epiglottitis is the one which killed the first president of the United States of America in 1799, namely: George Washington. "On a 14 December 1799 morning, George Washington woke up with a great pain at the pharynx. It quickly showed a fast-evolving stridor associated with a dysphonia. Being unable to lie down, he was treated standing though, in those days, the treatment consisted of a bleeding of more than 2 litres, on the night of that day, he died at 11.30 p.m." [1]. However, the first descriptions of acute epiglottitis in adult seem older. Roland de Palma might have described the first abscess of the epiglottis in the 13th century [2].

The epidemiology of acute epiglottitis has varied over time. It has firstly been described essentially in adults, because it was considered as rare in children and it is only after the 1950s that acute epiglottitis started occurring in children. In the 1960s, it had become an illness exclusively occurring in children. In the West, child vaccination campaigns preventing *Haemophilus influenzae type b (Hib)* had incredibly lowered the occurring rate of acute epiglottitis in

children. Acute epiglottitis became then an adult pathology. In 1980, the child/adult ratio was 2.6/1, and in 1990, it was only 0.4/1 [3].

It is hard to get a typical profile of patient types from the literature database. Patients of all ages can be concerned. Nevertheless, the average age of patients is between 40 and 50 years old according to the series, with sometimes, a male predominance [4, 5], as it is the clinical case of the patient under study. The occurrence of associated comorbidities is frequently found: between 8 to 82% of cases [[4, 5]. The most found comorbidities are diabetes, high blood pressure or immunodepression [4, 6, 7, 8]. We also notice a high smoking prevalence [4,8,9]. Non-insulin-dependent diabetes was the comorbidity found in the patient under study.

The clinical signs in adults are evoking enough but less brutal in children; associating a choked-up voice, an increasing swallowing difficulty with heavy drooling, all evolving in an infectious context (fever and hyperleukocytosis).

The clinical signs start, in healthy adults on the other hand, by a severe general pharyngeal pain which is a common sign. The other symptoms variably associate themselves. Frequently noted symptoms are the following: odynophagia with sometimes a reflexive otalgia, fever, an inconstant dyspnea more or less severe which disappears more often during the admission of the patient, an anterior cervical pain, a dysphonia with covered voice, a difficulty to swallow saliva with salivary stasis. Sometimes, the patient suffers from respiratory distress [10]. Generally, the symptoms show up quickly in the beginning, in 90% cases. In the case of the patient under study, symptoms were a laryngeal dyspnea associated with dysphonia, and fever.

Sometimes, the examination must be done in a sitting position. Contrary in children, it is not inappropriate to take a nasofibroscope in adults in case of acute epiglottitis suspicion. Flexible fibroscope is the reference examination to carry out which allows to confirm the diagnosis. In fact, it allows a direct visualization of the epiglottis which shows oedema and inflammation, thus eliminating the other clinical differential diagnosis (angioedema, isolated pharyngeal abscess, uvulitis, ...) [11]. Most of the time, we notice an attack associated with other supra-glottic structures represented by arytenoids, glosso-epiglottic and epiglottic ary folds. The proposed classification by Katori may be useful, in addition, it is more predictive of the necessity of a respiratory assistance [12]. The patient under study was classified at stage II in that classification.

The cervical CT scan can only be taken in stable patients, for whom the sitting position doesn't present any risk of obstructing upper airways. It allows to confirm the diagnosis and check for complications [13, 14, 15]. The cervicothoracic CT showed an epiglottic appeasement filling almost all the supra-glottis, the glottis, and the sub-glottis were free.

The treatment, of the patient under study, was on an associated systemic antibiotic therapy, a corticosteroid therapy and a close monitoring of the respiration. Our therapeutic protocol was an eventual intubation. The evolution was good with an outcome two month was normal. The use of an intravenous systemic corticosteroid therapy is largely described in the literature [10, 16]. The retrospective data are conflicting, but many authors find no significant difference as to the duration of hospitalization or invasive ventilation between patients who received or not a corticosteroid therapy [10, 17].

Conclusion

Considered, for a long time, as a pathology occurring in children, acute epiglottitis is a severe ENT pathology, which rarely adults suffer from. A diagnosis and an early treatment come to a total remission of the sickness.

References

1. Lewis FO. Washington's last illness. *Ann Med Hist* 1932; 4:245-8.
2. Howard RE. Laryngeal abscess. *Laryngoscope* 1931; 41:344-7.
3. EN-LIANg CHANG, and al. Adult acute epiglottitis: Experiences in a Taiwanese setting. *Otolaryngol Head Neck Surg.*2005; 132:689-69.
4. Bizaki AJ, Numminen J, Vasama JP, et al (2011) Acute supraglottitis in adults in Finland: review and analysis of 308 cases. *Laryngoscope* 121: 2107-13
5. Suzuki S, Yasunaga H, Matsuri H, et al (2015) Factors associated with severe epiglottitis in adults: analysis of a Japanese inpatient database. *Laryngoscope* 125: 2072-7
6. Berger G, Landau T, Berger S, et al (2003) The rising incidence of adult acute epiglottitis and epiglottic abscess. *Am J Otolaryngol* 24: 374-83 *J Laryngol Otol* 8:818-237.
7. Cheung CS, Man S, Graham CA, et al (2009) Adult epiglottitis: 6 years' experience in a university teaching hospital in Hong Kong. *Eur J Emerg Med* 16:221-6
8. Ovnat Tamir S, Marom T, Barbalat I, et al (2015) Acute supra-glottitis: changing trends. *Eur Arch Otorhinolaryng* 272:929-35
9. Chroboczek T, Cour M, Hernu R, et al (2015) Long-term outcome of critically ill adult patients with epiglottitis. *PLoS One* 10: e125736
10. Mayo-Smith MF, Spinale JW, Donskey CJ, Yukawa M, Li RH, Schiffman FJ. Acute epiglottitis. An 18-year experience in Rhode Island. *Chest* 1995; 108:1640-7.
11. Phelan DM, Love JB (1983) Adult epiglottitis: is there a role for the fiberoptic bronchoscope? *Chest* 86:783-4
12. Katori H, Tsukuda M. Acute epiglottitis: analysis of factors associated with airway intervention. *J Laryngol Otol* 2005; 119:967-72.
13. Chroboczek T, Cour M, Hernu R, et al (2015) Long-term outcome of critically ill adult patients with epiglottitis. *PLoS One* 10: e125736
14. Lee YC, Kim TH, Eun YG (2013) Routine computerised tomography in patients with acute supraglottitis for the diagnostic of epiglottic abscess: is it necessary? — a prospective multicenter study. *Clin Otolaryngol* 38:142-7
15. Smith MM, Mukherji SK, Thompson JE, et al (1996) CT in acute supraglottitis. *Am J Neuroradiol* 17:1355-8
16. Templier F, Lentz T, Tazarourte K, et al (2004) Benefit of pharmaceutical anti-oedematous treatment in acute adult epiglottitis. *Ann Fr Anesth Reanim* 23:1003-6
17. Guardiani E, Bliss M, Harley E, et al (2010) Supraglottitis in the era following widespread immunization against *Haemophilus influenzae* type b: evolving principles in diagnosis and management. *Laryngoscope* 120:2183-8