

## Peritoneo-Vaginal Leaks in Peritoneal Dialysis: A Report of 3 Cases

M. Jdidou\*, S. Elmakkoul, N. Hmaidouch, N. Ouzeddoun, L. Benamar

Nephrology Department-Dialysis and Renal Transplantation Ibn Sina University Hospital-Rabat, Morocco

\*Corresponding author: Mariam Jdidou, Specialist Doctor of Nephrology, CHU IBN SINA Rabat Morocco. Email: Jdidou.mariam@gmail.com

**Citation:** Jdidou M, Elmakkoul S, Hmaidouch N, Ouzeddoun N, Benamar L (2024) Peritoneo-Vaginal Leaks in Peritoneal Dialysis: A Report of 3 Cases. American J Cas Rep Rev: AJCRR-106.

**Received Date:** 11 March, 2024; **Accepted Date:** 15 March, 2024; **Published Date:** 20 March, 2024

## Summary

**Introduction:** Peritoneal dialysis (PD) is an extra-renal purification technique indicated for patients with end-stage kidney disease (ESKD). Although it has many advantages, it also has a number of complications, such as peritoneo-vaginal leakage of dialysate.

**Patients and method:** We conducted a retrospective study from June 2013 to December 2021, including three patients with peritoneo-vaginal leakage occurring in PD.

**Results:** Three male patients, aged 70, 50 and 77 respectively, with ESKD were placed on PD. All three patients presented with inadequate drainage and the progressive appearance of bilateral hydrocele, which occurred one year (late leakage), two and four days (early leakage) respectively after the initiation of exchanges.

The etiological investigation led to the conclusion of a peritoneo-vaginal leak associated with an inguinal hernia in only one case.

The two cases of early leakage were treated by temporary suspension of PD, with a good response in one case and failure in the second, leading to his definitive transfer to haemodialysis (HD); however, the hernia repair enabled immediate resumption of PD in the third patient.

**Discussion and conclusion:** Peritoneo-vaginal leakage is a rare mechanical complication in PD. The clinical examination plays an essential role in confirming the diagnosis and in the therapeutic decision. If the diagnosis is uncertain, or if there is a clinical need to show the anatomy of the leak, an imaging approach becomes desirable.

This complication should not prevent the progression of PD in the management of patients with ESKD.

## Introduction

Peritoneal dialysis (PD) is a replacement technique widely used for patients with end-stage kidney disease (ESKD). It has many advantages, but also some complications, such as peritoneovaginal leakage, a rare mechanical complication corresponding to a loss of peritoneal cavity tightness, with dialysis fluid passing outside the abdominal cavity via inguinal hernias or a persistent peritoneovaginal canal (1,2,3).

We conducted a retrospective study from June 2013 to December 2021, including three patients with peritoneo-vaginal leakage occurring in PD.

## Case reports

**Observation 1:** 70-year-old patient with ESKD due to nephroangiosclerosis, started on PD in May 2012 with two 2-liter exchanges per day with good purification and ultrafiltration (Residual renal function (RRF) > 2ml/min).

One year after the start of exchanges (June 2013), the patient presented with bilateral hydrocele more significant on the right, without signs of overload with temporary suspension of PD and optimisation of the dose of diuretics (1g of furosemide). The scrotal oedema disappeared one week after PD was stopped. Resumption of small-volume exchanges (1-liter) was responsible for the reappearance of the hydrocele. Suspicion of a peritoneo-vaginal leak led to a thorough clinical examination, which revealed a right inguinal hernia. An abdomino-pelvic ultrasound showed a persistent right peritoneo-vaginal canal,

measuring 14 mm, with passage of small intestine into scrotum. The diagnosis of inguino-scrotal hernia on persistence of the peritoneo-vaginal canal was retained and the patient benefited from a hernia cure with closure of the peritoneo-vaginal canal and immediate resumption of exchanges (2 exchanges of 2-liter/day) until 2016. He then died of a dyspnoea pneumonia caused by Aspergillosis.

**Observation 2:** Patient aged 50, ESKD with undetermined nephropathy, was put on PD in 2017 with 2 exchanges per day. Two days after the start of exchanges, the patient presented with bilateral hydrocele. Examination of the hernial orifices was free, abdomino-pelvic ultrasound revealed no abnormalities apart from a right epididymal cyst. The diagnosis of a peritoneovaginal leak was evoked, leading to the suspension of PD for 3 weeks, with a marked regression of the hydroceles as a result. Resumption of exchanges with a gradual increase in injection volumes 1 month after (VI= 2litres) was uneventful.

**Observation 3:** A 77-year-old patient with ESKD due to diabetic nephropathy since 2019 was put on PD in March 2021. 4 days after starting exchanges, the patient presented a loss of ultrafiltration with progressive appearance of a bilateral hydrocele. Temporary cessation of PD for 1 month and resumption of exchanges by automated peritoneal dialysis (APD) with small infusion volumes did not allow the hydrocele to disappear. A peritoneovaginal leak was suspected. The patient refused all radiological exploration and the closure of the peritoneo-vaginal canal, hence his definitive transfer to HD.

## Discussion

PD is an endocorporeal dialysis method that uses the peritoneum as a membrane for exchanges between the blood and the dialysis fluid. Complications may compromise the success of this technique; they may be immediate or delayed, of infectious or mechanical origin, in particular dialysate leakage, which results from an increase in intra-abdominal pressure associated with dialysate perfusion (4) and consequently predisposes to hernias and leaks.

Their early detection, both clinically and radiologically, is essential in order to reduce transfer to HD (5).

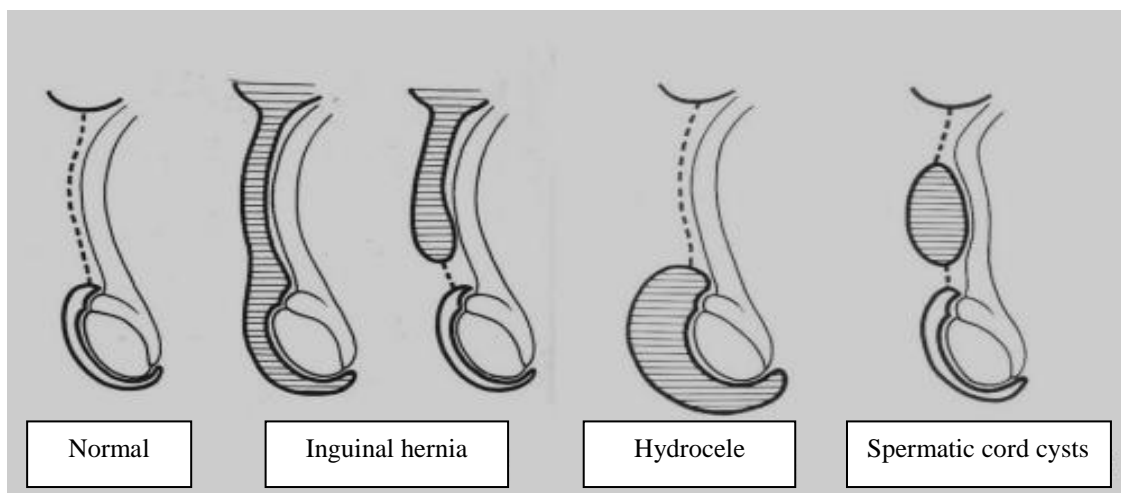
The incidence of dialysate leaks reported in the literature varies considerably, making accurate estimation of this complication difficult, as the majority of studies have been limited to a single type of leak.

Peritoneo-vaginal and pleural leaks are the main mechanical complications in PD patients, occurring in more than 5% of

patients on continuous ambulatory peritoneal dialysis (CAPD) (1,6).

Indirect inguinal hernias are the most frequent cause of this pathology, with an incidence ranging from 0.8 to 4.4% (6).

Pathologies of the peritoneo-vaginal canal are congenital affections due to the persistence of the canal, which is an excrescence of the parietal peritoneum crossing the abdominal wall towards the scrotum in men and the labia majora in women. It is in place by the 3rd month of intrauterine life and gradually obliterates between the 8th and 9th months to form Cloquet's ligament (7). Failure of this duct to close will be the cause of four anatomic-clinical entities: communicating or non-communicating hydroceles, inguinal or inguino-scrotal hernias, and spermatic cord cysts (Figure 1) (8,9). The latter is evident in 90% of infants at birth, but only around 15% of adult men have a patent duct. Non-obliteration of the duct may remain clinically silent for life, or only become evident in specific cases, such as the onset of PD (10).



**Figure 1 (9):** Abnormal closure of the peritoneovaginal canal.

Peritoneo-vaginal leakage in PD is due to increased intra-abdominal pressure and loss of peritoneal membrane integrity, although the most frequent cause is fluid extravasation from an indirect hernial sac or persistence of the peritoneo-vaginal canal (1).

Patients undergoing PD have an increased risk of inguinal hernia, particularly in at-risk populations: multiparous women, the elderly, obese patients, patients with polycystic kidney disease or patients undergoing long-term corticosteroid treatment (11).

Peritoneovaginal leaks tend to develop during the first year of PD (late leaks), whereas early leaks are generally observed within 30 days of PD catheter insertion (12). In our series, peritoneovaginal leakage was late in one case and early in two patients occurring within two and four days respectively of initiation of PD exchanges.

There are several clinical manifestations. They can be diagnosed by loss of ultrafiltration (UF), weight gain, or clinically by the appearance of a hydrocele, uni or bilateral. In the case of bursal swelling, transillumination (a light source behind the scrotum) can be used to distinguish whether the swelling is liquid or solid, thus confirming the diagnosis of hydrocele (13).

The clinical examination plays an essential role in confirming the diagnosis and in the therapeutic decision. If the diagnosis is uncertain or if there is a complication or a clinical need to show the anatomy of the leak, an imaging approach becomes desirable.

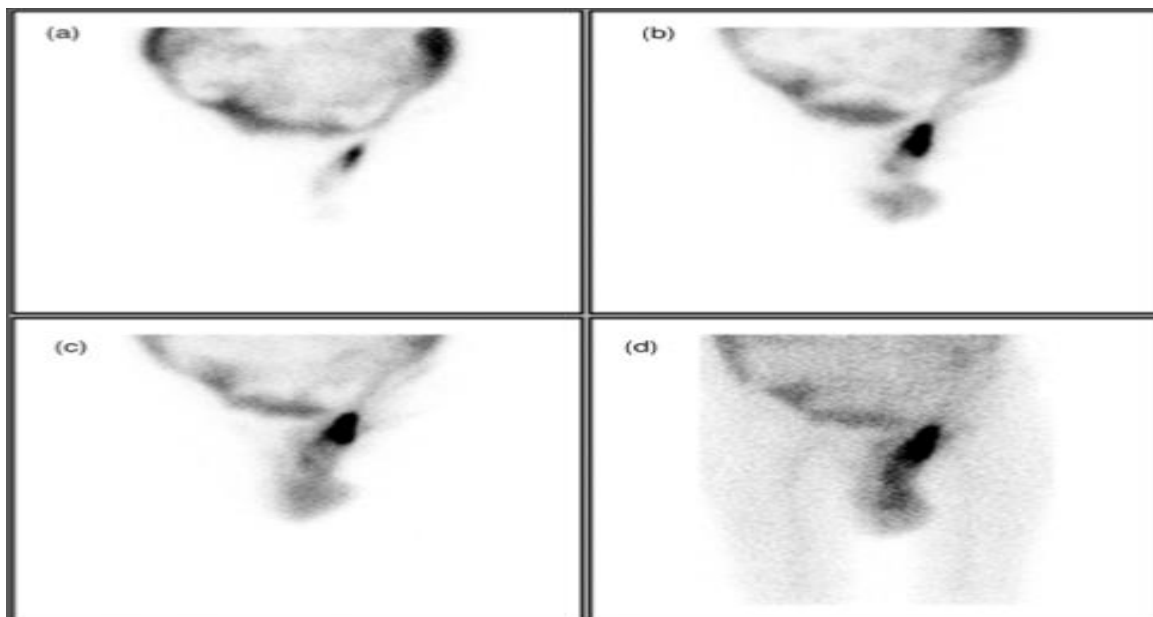
Abdomino-pelvic ultrasound plays an important role in establishing the diagnosis and assessing complications. It is necessary to demonstrate the persistence of the peritoneo-vaginal canal and to assess the contents of the hernia sac and the vascularisation of incarcerated structures in the event of an associated hernia.

Peritoneography by computed tomography (CT) remains the reference examination due to its simplicity, accessibility and ease of use, enabling the entire peritoneal cavity to be explored. This examination confirms the diagnosis and makes it possible to establish a precise lesion assessment in the event of associated hernia (14,15). It consists of opacifying the peritoneal cavity by injecting iodinated contrast product (ICP) into the dialysate infused into the patient. The patient should be advised to mobilise before the examination to distribute the ICP more evenly and allow it to diffuse into the breach.

Peritoneography can also be performed using magnetic resonance imaging (MRI) with injection of Gadolinium into the peritoneal cavity, indicated in cases of allergy to PCI.

Peritoneal scintigraphy with isotope injection into the peritoneal cavity is a simple, non-invasive, low-radiation examination with no risk of allergy, enabling peritoneo-vaginal leaks to be diagnosed and located, thanks to the possibility of acquiring images both at the time of infusion and at a distance and after

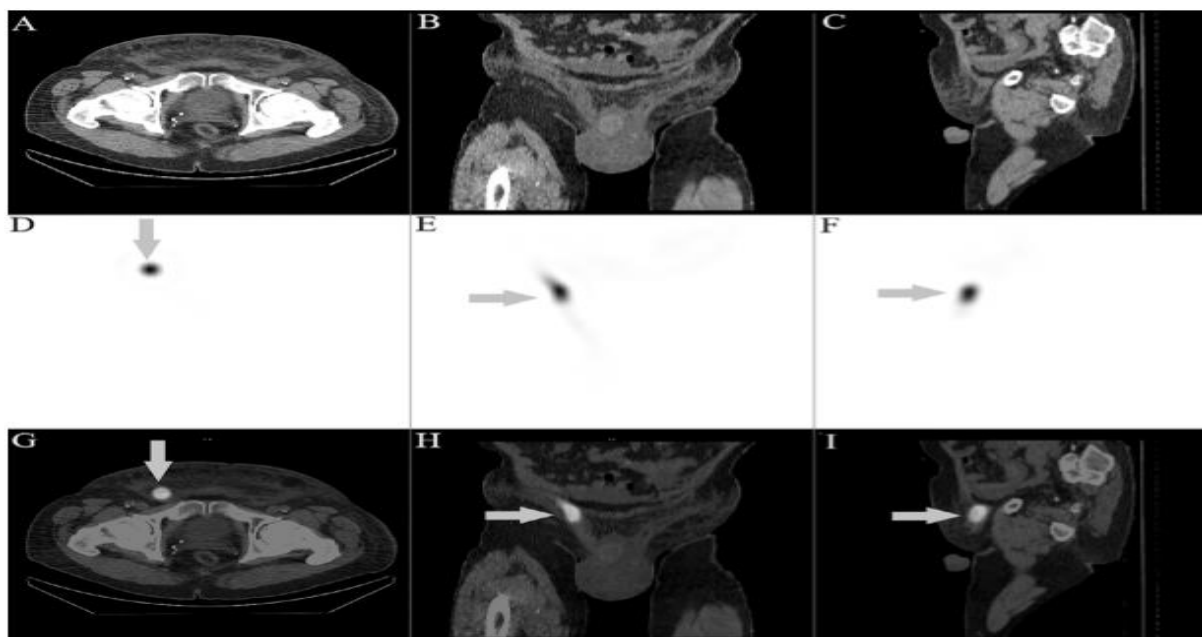
drainage of the dialysate. This test is highly sensitive for detecting small-volume leaks. It involves injecting an isotopic tracer (Technecium 99m) into the dialysate, which is infused into the peritoneum. Acquisitions are made every 5 minutes for 1 hour (16) (Figure 2).



**Figure 2 (10):** 99mTechnetium (99mTc) sulphur colloid scintigraphy showing peritoneo–scrotal communication: (a) 20 min static image showing tracer distribution within the peritoneal cavity; (b,c) movement of tracer into the left side of the scrotum at 1 and 3 h; (d) image at 5 h following i.v. 99mTc pertechnetate injection: the path of tracer movement into the scrotum is seen against background body activity.

The new generations of gamma cameras can be used to produce scintigraphic images (SPECT) coupled to the CT (SPECT/CT: Single Photon Emission Computed Tomography / Computed Tomography) with the aim of merging the images obtained by each modality to obtain a mixed image (hybrid imaging). The principle involves injecting a radioactive tracer that emits

gamma rays. The SPECT camera detects the rays emitted and generates an image in all 3 spatial planes. These techniques increase the sensitivity and specificity of the examination and provide better anatomical location if a small leak is suspected (16, 17, 18).



**Figure 3 (19):** At 5 hours postinjection of 99mTc-MAA, further evaluation with low-dose CT with axial (A), coronal (B), and sagittal views (C), corresponding SPECT (D-F) and fusion SPECT/CT imaging (G-I) localized the uptake (arrows) at the right inguinal canal, consistent with a patent processus vaginalis. The axial fusion image (G) clearly demonstrates the uptake at the superficial inguinal ring, an extraperitoneal structure. The coronal (H) and sagittal (I) fusion images further illustrates the communication between the peritoneum and the right inguinal canal.

In our unit, two patients underwent abdomino-pelvic ultrasound imaging, which showed an inguino-scrotal hernia with persistence of the peritoneo-vaginal canal in one patient, and a right epididymal cyst in the second. The diagnosis of peritoneovaginal leakage was clinically evoked in all three cases.

Approaches to the management of peritoneo-vaginal leaks and current data are insufficient to state which option is the best in this respect. Several treatment modalities for dialysate leaks have been advocated, including surgical repair, temporary transfer to HD, and supine APD with small volumes (500 to 1500ml) leaving the peritoneal cavity empty during ambulatory periods (20).

According to the literature, for early leaks, temporary cessation of dialysis for 1 to 3 weeks generally results in spontaneous cessation of the leak. Surgery is only indicated in the event of recurrence (1, 21). For late leaks, transfer to HD, DPA or surgery are various treatment options, although surgical treatment has been suggested to offer longer remission periods without recurrence (1, 22,23).

In the case of an associated hernia, surgical management must ensure a perfectly tight closure so that the patient can immediately continue PD postoperatively without going to HD (24).

In our unit, the two cases of early leaks were treated by temporary suspension of PD, with a good response in one case and failure in the second, leading to definitive transfer to HD; however, the hernia repair enabled immediate resumption of PD in the third patient without going to HD.

## Conclusion

Peritoneo-vaginal leakage is a rare mechanical complication in PD. Clinical examination plays an essential role in confirming the diagnosis and in the therapeutic decision. This complication should not prevent the progression of PD in the management of patients with ESKD, for which the ISPD 2019 (25) recommends:

- We recommend that initiation of dialysis following catheter placement be delayed for 2 weeks when possible to minimize the risk of leaks (1B).
- We recommend that acute and urgent start of PD 2 weeks following catheter placement utilize a recumbent, low volume, intermittent dialysis regimen, leaving the peritoneal cavity dry during ambulatory periods to minimize the risk of leak (1C).
- We recommend the use of CT peritoneography or peritoneal scintigraphy to investigate suspected peritoneal boundary dialysate leaks (1A).

## \*Authors Contribution

### \*Ethical Statement

- ✓ The authors participated in revising the article substantially in terms of both substance and form.
- ✓ Les patients have given their consent for the work
- ✓ No conflicts of interest
- ✓ I didn't have any funding.

## Declaration

### 1. Agree to Conditions:

- 1) All authors of the manuscript have read and agreed to its content and are accountable for all aspects of the accuracy and integrity of the manuscript;
- 2) The submitted article is the one presenting original work that is not considered or reviewed by any other publication and has not been published elsewhere in the same or a similar form.

### 2. Author-Related Information:

Department of Nephrology at the University Hospital Center Ibn Sina, Rabat, Morocco

Faculty of Medicine and Pharmacy, Rabat, Morocco

#### **Mariam Jdidou**

Specialist Doctor

Jdidou.mariam@gmail.com

#### **Sara Elamakkoul**

Specialist Doctor

saraelmkl@gmail.com

#### **Nabil Hmaidouch**

Resident Doctor

hmaidouchn@gmail.com

#### **Naima Ouzeddoun**

Associate Professor

ouzeddoun.naima@hotmail.fr

#### **Loubna Benamar**

Associate Professor

loubna24@yahoo.fr

## References

1. Leblanc.M, Ouimet.D, Pichette.V : Dialysate Leaks in Peritoneal Dialysis. Semin Dial. févr 2001;14(1):50 4.
2. Bellavia.S, Coche.E, Goffin.E : [Exploration of ultrafiltration failure in peritoneal dialysis. Nephrol Ther. déc 2008;4(7):590 6.
3. Stuart.S, Booth.TC, Cash.CJC, Hameeduddin.A, Goode.JA, Harvey.C et al. Complications of continuous ambulatory peritoneal dialysis. Radiogr Rev Publ Radiol Soc N Am Inc. avr 2009;29(2):441 60.
4. Gokal.R : Peritoneal dialysis in the 21st century : an analysis of current problems and future developments. J Am Soc Nephrol, 2002, 13 Suppl 1: S104-116.
5. Harris.SA, Lamping.DL, Brown.EA, Constantinovici.N : Clinical outcomes and quality of life in elderly patients on peritoneal dialysis versus hemodialysis. Perit Dial Int, 2002, 22: 463-470.
6. Eduardo.TJ, Pilar.RO, et al. Genital leakage associated with patent peritoneo-vaginal duct and polycystic kidney and liver disease in patients on peritoneal dialysis. Nefrologia (2013), 33(2).0-288.
7. Sarr.A, Sow.Y, Fall.B, C. et al: La pathologie du canal péritonéo-vaginal en pratique urologique. Progrès en urologie 2014(24), 665—669.
8. Estalellaa.L, Carlos.RO, Jordi.G, et al. Hydrocele After Peritoneal Dialysis: Persistence of the Peritoneal-Vaginal Duct. CIRUGIA ESPAN OLA 2014 (2), 907.
9. BEVAN.AD. The surgical treatment of the undescended testicle. J.A.M.A. 1903 ; 15 : 153.
10. Bhattacharya.A, Mittal.BR.Peritoneo-scrotal communication: demonstration by 99m technetium sulphur colloid scintigraphy. Australas Radiol 2005;49(4):335-7.

11. Rocco MV, Stone WJ. Abdominal hernias in chronic peritoneal dialysis patients: a review. *Perit Dial Bu* 1985;3: 171-4.
12. Lam .MF, Lo.WK, Tse .KC, et al. Retroperitoneal leakage as a cause of acute ultrafiltration failure: its associated risk factors in peritoneal dialysis. *Perit Dial Int J Int Soc Perit Dial*. oct 2009;29(5):542 7.
13. Prischl FC, Muhr T, Seiringer EM, et al. Magnetic resonance imaging of the peritoneal cavity among peritoneal dialysis patients, using the dialysate as “contrast medium.” *J Am Soc Nephrol*. 2002;13: 197–203.
14. Covington .MF, Choudhary. G, Avery. RJ, et al. Optimal time points for scintigraphic imaging of pleuroperitoneal shunts. *Clin Nucl Med*. 2016; 41:766–768.
15. Covington .MF, Choudhary. G, Avery.RJ, Kuo. PH. Pitfalls in the performance and interpretation of scintigraphic imaging for pleuroperitoneal shunt. *Clin Nucl Med*. 2016;41: 858–861.
16. Farid.K, Guyo. M, Jeandot.R, Durieux.M, et al. SPECT-CT improves detection of small peritoneal fistula. *Clin Nucl Med*. 2009;34: 634–635.
17. Chen.YC, Su.YC, Chiu .JS, Wei.CK, Wang.YF. Peritoneo-scrotal shunting diagnosed by Tc-99m DTPA SPECT/CT imaging. *Kidney Int*. 2010; 78:523.
18. Tun.KN, Tulchinsky.M. Pericatheter leak in a peritoneal dialysis patient: SPECT/ CT diagnosis. *Clin Nucl Med*. 2012;37: 625–628.
19. Wilson.T, Owen. K, et al. Peritoneal-scrotal dialysate leakage demonstrated on SPECT/CT imaging in a patient on peritoneal dialysis. *Radiology case reports*. 2022 ;17: 2643-2646.
20. Crabtree.JH. Hernia repair without delay in initiating or continuing peritoneal dialysis. *Perit Dial Int* 2006; 26:178–82.7.
21. Litherland.J, Gibson.M, Sambrook.P, Lupton, et al. Investigation and treatment of poor drains of dialysate fluid associated with anterior abdominal wall leaks in patients on chronic ambulatory peritoneal dialysis. *Nephrol Dial Transplant Off Publ Eur Dial Transpl Assoc - Eur Ren Assoc*. 1992;7(10):1030 4.
22. Jegatheswaran.J, Warren. J, Zimmerman. D. Reducing intra-abdominal pressure in peritoneal dialysis patients to avoid transient hemodialysis. *Semin Dial*. mai 2018;31(3):209 12.
23. Tzamaloukas.AH, Gibel.LJ, Eisenberg.B, et al. Early and late peritoneal dialysate leaks in patients on CAPD. *Adv Perit Dial* 6:64–70, 1990.
24. Boyer.A, Bonnamy.C, Lanot. A, et al. How to manage abdominal hernia on peritoneal dialysis. *Nephrol Ther*. mai 2020;16(3):164 7.
25. John.HC, Badri.MS, Kai-Ming .C, Ana E.F, Johan .VP. IPD GUIDELINES CREATING AND MAINTAINING OPTIMAL PERITONEAL DIALYSIS ACCESS IN THE ADULT PATIENT: *Peritoneal Dialysis International* 2: 14-15,2019.

**Copyright:** © 2024 Jdidou M. This Open Access Article is licensed under a [Creative Commons Attribution 4.0 International \(CC BY 4.0\)](https://creativecommons.org/licenses/by/4.0/), which permits unrestricted use, distribution, and reproduction in any medium, provided the original author and source are credited.